

Clinical application of zirconia implants

Results from comparative studies

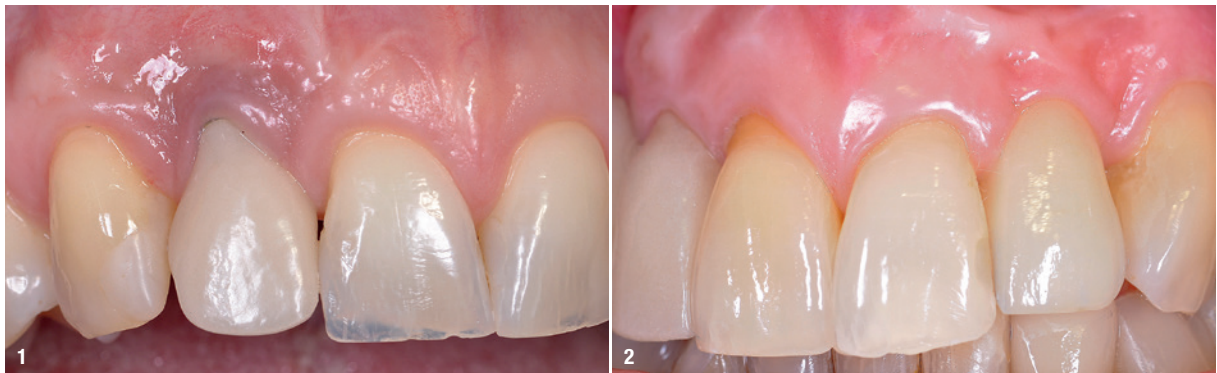
Dr Elisabeth Jacobi-Gresser, Germany

Since the market entry at the end of the 1990s, the number of inserted zirconium oxide implants has been steadily increasing. Today, however, they constitute only an estimated 3 to 5 % of all inserted implants worldwide. Market analyses predict a significant rise in the coming years (Dental Implants Market Research Report 2017). This trend is due to the increasing confidence in the material zirconium oxide, the evolution from one-piece to two-piece configuration, as well as optimised abutment connections on ceramic implants.

Compared to titanium implants, one-piece zirconium oxide implants have shown equally good results in clinical studies with regard to osseointegration. In addition, they have obvious advantages in terms of soft-tissue acceptance. Titanium and zirconium both belong to the group of transition metals in the periodic table of elements. However, the physicochemical properties of these two metals and their oxides differ significantly. While titanium inside of a biological system is subject to tribocorrosion and subsequently triggers immunological reactions, the completely oxidised and sintered material zirconium dioxide is characterised by excellent corrosion resistance and therefore has a high biological compatibility.^{11,19} In a meta-analysis on titanium implants, the weighted average for the occurrence of mucositis was 43 % and for peri-implantitis it was 22%.⁹ There is a correlation between peri-implantitis and a reduced implant function

time. The success rate of zirconium oxide implants of the younger generation is comparable to that of titanium implants.^{2,15,24,26} For one-piece implants made of alumina toughened zirconia (ATZ), the three-year success rate is 98.5 % and five-year success rate is 94.3 %. The seven-year success rate for one-piece implants made of yttria-stabilised zirconia (Y-TZP) is 88.6 %. The occurrence of fractures is generally rare, but it is observed with Y-TZP implants of the first generation owing to the use of diameter-reduced implants, aggressive surface treatment (aluminium powder blasting) during production, incorrect loading with an unfavourable implant-crown axis, occlusal overload, and bruxism.²⁹

The availability of two-piece implants made of the more durable ATZ ceramics for ten years now extends the range of indications and facilitates clinical application. These factors contribute significantly to the further rise of ceramic implants and it is expected that they will be used even more strongly in the future. In addition to the advantages in the aesthetic zone owing to the white colour, the relatively low biofilm adhesion, as shown in *in vitro* and *in vivo* studies, and the higher corrosion resistance compared to titanium are emphasised in the literature.^{1,5,25,26,19} The aesthetic advantages that the implant material zirconium oxide has over titanium, especially in the anterior aesthetic zone, are particularly evident in patients with thin gingiva of less than 2 mm (Figs. 1 & 2).³²



Figs. 1 & 2: Aesthetic advantages of the implant material zirconium oxide (region #22) compared with the titanium-based material.

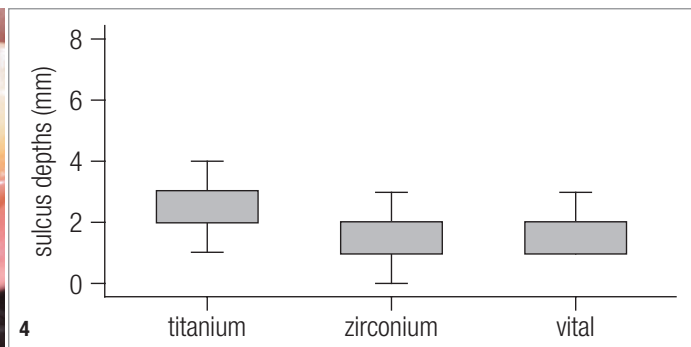
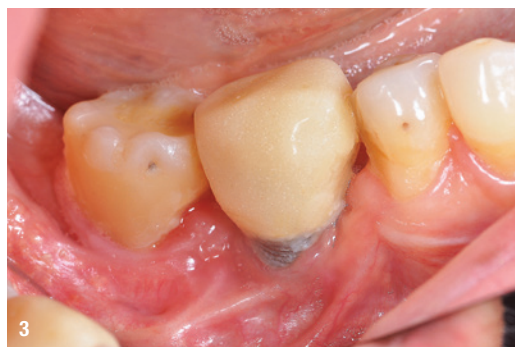

Fig. 3: Microbial load around a titanium implant in a patient with peri-implantitis. **Fig. 4:** The sulcus depths of titanium implants differ in a statistically significant way from the ones of zirconium oxide implants ($p = 0.03$). The average value of titanium implants is 2.3 mm, whereas the average value of zirconium oxide implants is at 1.8 mm (personal and unpublished data).

Possible effects of titanium implants

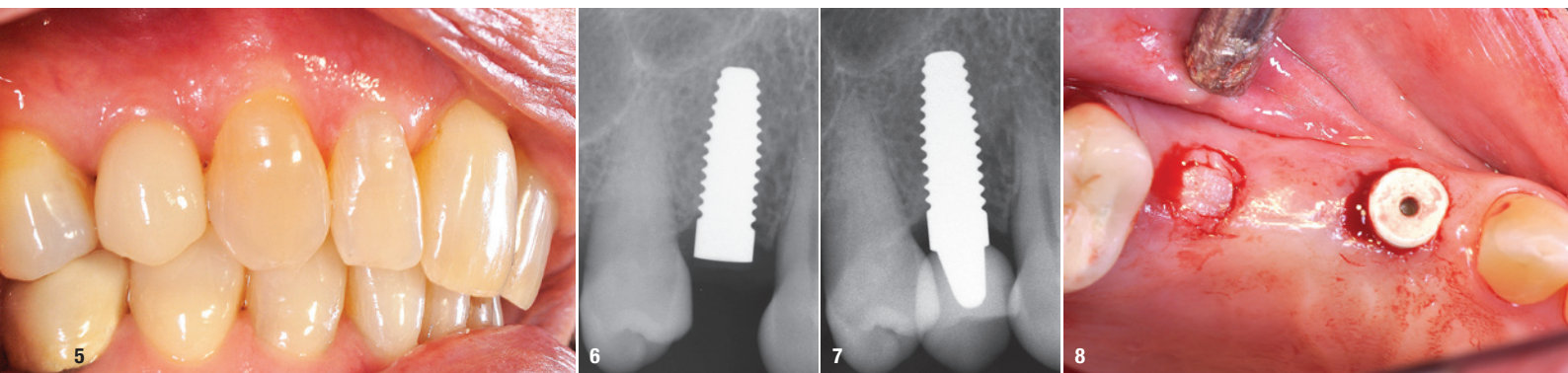
Comparative studies have examined the toxicological effects of nano-/microparticle load in tissues in addition to immunological-inflammatory parameters. They found increased formation of free radicals (ROS) in titanium particles compared to zirconium oxide particles.¹⁹ Lipopolysaccharides (LPS) in bacterial membranes of periodontal-pathogenic germs and titanium particles stimulate inflammasomes in macrophages, resulting in a release of the pro-inflammatory cytokine interleukin-1. The stimulation effect by titanium particles was enhanced in LPS-exposed (*Aa*, *Pg*, *e.coli*) macrophages. Titanium ions alone do not affect the transcription of inflammasomes. The amount of titanium found in peri-implant tissues was enough to stimulate the release of IL-1b *in vitro*.^{22,23} Microbial adhesion in the oral cavity additionally promotes the corrosion tendency on titanium implant surfaces. This milieu-altering microbial influence by periodontal early colonisers is reflected in the development of mucositis and peri-implantitis. It also triggers surface corrosion on the titanium implant which, in turn, leads to an increase in metal deposits (Fig. 3).³⁰

As a consequence, the microbiome shifts from the “healthy” diversified to a pathological and less diversified germ load. The correlation between the amount of titanium corrosion products in the peri-implant tissue and the presence of peri-implantitis has been proven. The amount of particles found in inflamed peri-implant tissue was eight times higher compared to the tissue around “healthy” implants, which had no or only a low particle load. The authors argue that these findings confirm the correlation between corrosion products and peri-implantitis and that they also confirm the role of corrosion products in modifying the peri-implant microbial structure and diversity.^{7,28} An evaluation of various inflammation markers in the tissue around implant healing caps made of titanium compared with zirconium oxide revealed that there is significantly higher evidence of inflammation when titanium is used in relation to all markers

investigated.⁸ Significantly increased systemic markers for “silent inflammatory” processes were also found in patients with grade V titanium implants (titanium alloy $TiAl_6V_4$), which had been *in situ* for more than ten years in combination with amalgam fillings, compared with the control group with neither implants nor fillings and also with the patient group who had amalgam fillings but no implants.¹⁸ Histopathological examinations of rare oral soft- and hard-tissue pathologies associated with titanium implants show an increased particle load.²¹ In the various extra- and intraosseous tissue lesions (with the exception of the traumatic bone cyst and the intraosseous metastasis of a renal carcinoma) an increased titanium particle load associated with inflammatory processes was found in 52.9% of the 68 cases. The question arises whether these titanium particles could be involved in the development of these lesions as a promoting aetiological factor.

Clinically stable peri-implant tissue conditions around zirconia

Preclinical and clinical studies on periodontological parameters around “healthy” titanium and zirconium implants have shown that there are statistically significant differences with regard to sulcus depths.¹⁶ The values prove to be higher for titanium implants than for zirconium oxide implants both in animals as well as in humans. As experience shows, sulcus probing on zirconium implants is more difficult owing to the dense fibrous tissue structure (Fig. 4). More than ten years of clinical experience confirm the stable peri-implant soft-tissue conditions and the lower incidence of peri-implantitis, which can develop if adhesive residues remain after abutment and crown fixation or if titanium particles remain in the tissue after loss of a titanium implant and re-implantation of a zirconium oxide implant in the same site or in close proximity (Figs. 5–7). Comparative analyses of the structure and the purity of ceramic implant surfaces were done on various Y-TZP and ATZ implants, which showed that all systems differ in their surface morphology and



Figs. 5–7: Stable peri-implant bone situations over the course of eight years. **Fig. 8:** Tissue collection at implant uncovering.

none of them show any impurities that could cause undesired adverse immunological reactions.⁴ In dynamic load tests and tests on the hydrothermal ageing of ATZ implants, high fracture resistance (> 1,100N), low expansion of the monoclinic phase layer on the surface and no change in surface roughness were found.³¹

Histological and photometric tissue analyses

In a pilot study on initially 43 tissue samples around two-piece ATZ implants, analyses were carried out with regard to the particle load in the tissue and corresponding inflammatory reactions. The tissue samples were collected at the uncovering of two-piece ZrO₂ implants (Zeramex® T implants, Dentalpoint; alumina-toughened

zirconia = ZrO₂ 76%, Al₂O₃ 20%, Y₂O₃ 4%) three to four months after implant insertion. Until today, more than 200 samples have been histologically and photometrically examined in another study (Fig. 8).¹⁴ The biopsies were fixated in 20% formalin solution and embedded in paraffin. The evaluation of the histological preparations was done by the Department of Oral Pathology of the University of Buenos Aires (Prof. Daniel G. Olmedo). In all samples a fine-particle material was detected, they showed epithelial hyperplasia and dense cell infiltrates without detectable foreign giant cells. The histological findings differ from those around titanium implants, which show a loose tissue structure, focal accumulations of titanium particles of different shape and size with macrophage and lymphocyte infiltrations, as well as a higher number of blood vessels. In addition to various metals detected in the EDS analysis, the accumulation of aluminium is considered conspicuous, which is not only ubiquitously distributed in our environment but is also present in ATZ zirconium oxide ceramics in concentrations of up to 20%. However, small amounts of aluminium could also be detected in the tissue of healthy volunteers without ATZ implants by means of multi-element analysis (Table 1). The remaining metals detected are for the most part not due to the use of the implant material zirconium oxide, but are relics from earlier dental restorations (Figs. 9–11). This could be demonstrated in individual patient cases.

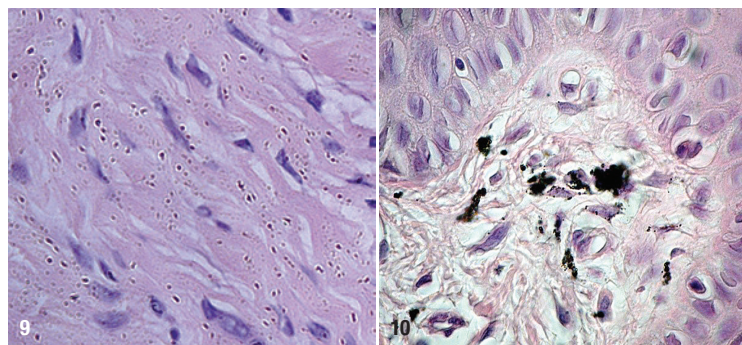


Fig. 9: Zirconium oxide particles are equally distributed in the peri-implant tissue (200x magnification). **Fig. 10:** Titanium oxide particles in the tissue (200x magnification).

Studies on the corrosion resistance of zirconium oxide

To analyse the corrosion resistance and the possible tissue load owing to particles released from the zirconium oxide implant surface, ten ATZ test discs were inserted in animals. The peri-implant tissues as well as the control tissues were examined after a period of six months. The test bodies were obtained by cutting them from the original ATZ implant bodies. Once the obtained tissue samples had been plasma cleaned, they were divided and subjected to histological examination and EDS analysis (evaluation of particles) on the one hand and to multi-

Element	Weight %	Atomic %
C	54.41	60.14
N	18.93	17.94
O	26.21	21.75
Al	0.17	0.08

Table 1: EDS analysis: control group without implants, aluminium detection in oral tissue.

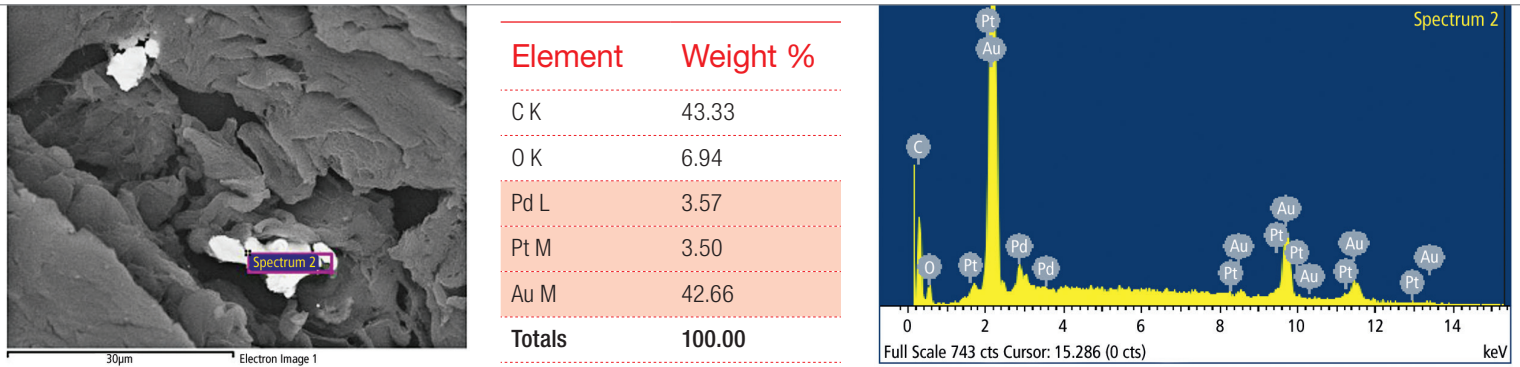
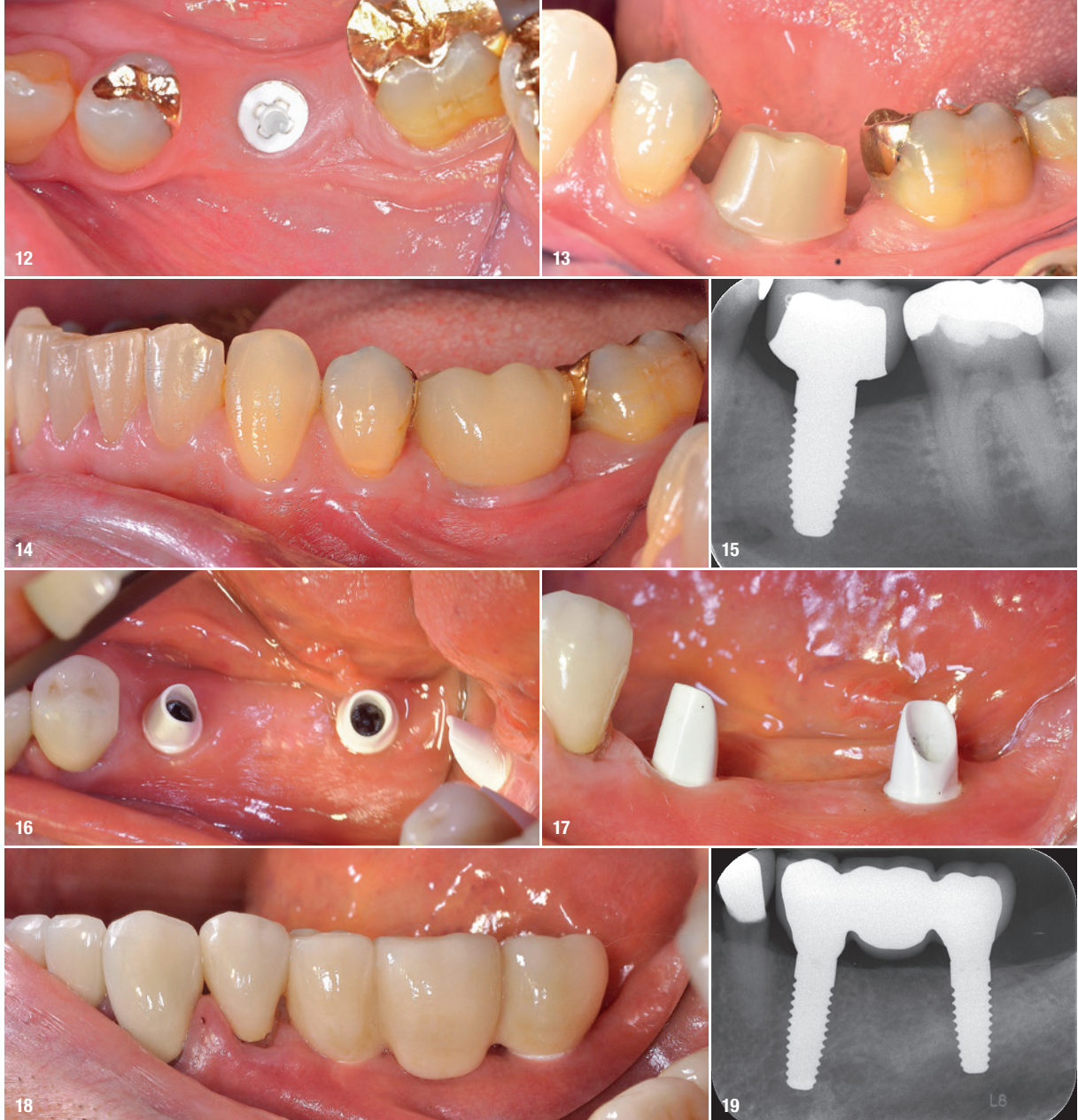


Fig. 11: SEM-EDS analysis (clinical case: evident residues of gold, platinum and palladium detected in tissue sample of patient with preceding year-long metal-ceramic bridge construction).

element analysis (ICP-MS) on the other in order to assess the aluminium and zirconium concentrations. In addition to the detected aluminium and zirconium particles between cells, and also intracellularly in macrophages, a significantly higher number of mast cells could be detected compared to the control tissues.¹⁴ Presumably, the particle debris is due to the test implant surface not being finalised and finished in the way that commercially-available implants usually are by the manufacturers. To clarify this, a similar series of investigations was done

with ATZ test discs that had the certified implant surface by the manufacturer. Further histochemical examinations (CD 34, CD 45, VEGF, CD 68) to evaluate immunological reactions as well as investigations on particle migration from peri-implant tissue around zirconium oxide implants into the body and the potential risk for organs are planned. Results of a recent study confirm the different corrosion behaviour of titanium and zirconium oxide surfaces in animals. Twelve weeks after implantation in the maxillae of mini-pigs, titanium and zirconium deposits




Figs. 12–19: Single crown and bridge construction on reversibly screw-retained zirconium oxide implants *in situ* and radiographic control images after insertion of the definitive prosthetics.

were detected in the peri-implant tissue. The tissue load with the corresponding implant materials was twice as high around the titanium implants than around the zirconium oxide implants. The cytotoxic effects and DNA damage caused by material nanoparticles, which were also measured, were significantly higher for titanium than for zirconium oxide.

Conclusion

In preclinical and clinical studies, zirconium oxide implants convince with good osseointegration, good material stability, good immunological/toxicological compatibility, good hard- and soft-tissue stability and convincing aesthetic results (Figs. 12–19). Reversible screw-retained two-piece implant systems allow an expansion of the prosthetic indications beyond single-tooth and bridge restorations. In individual cases, hybrid prosthetic constructions with telescopes and locators as connecting elements have been realised in the past three years.

However, there is currently still a lack of clinical evidence in this regard. As is expected, corresponding scientific studies on zirconium oxide implants to assess their long-term success and the associated biological complications beyond ten years have yet to be completed.



contact



Dr Elisabeth Jacobi-Gresser

c/o GP Dres. Igiel, Knierim
und Kollegen
Heidesheimer Straße 20
55124 Mainz
Germany
mail@jacobi-gresser.de
www.jacobi-gresser.de

Author details

